International Journal of Research and Review
[Indexed, Peer-Reviewed Journal]
Volume 13; Issue: 11; November 2026
Website: www.ijrrjournal.com
E-ISSN: 2349-9788; P-ISSN: 2454-2237

Occipital Lobar Intracerebral Hemorrhage in a Normotensive 37-Year-Old Man: A Case Report

Tasia Irma Endriani[1], Ni Wayan Bunga Pandansari[1], Desie Yuliani[2], Ni Made Kurnia Dwi Jayanthi[2]

[1]Intern-Department of Neurology, Wangaya Regional General Hospital, Denpasar, Bali, Indonesia
[2]Neurologist-Department of Neurology, Wangaya Regional General Hospital, Denpasar, Bali, Indonesia

Corresponding Author: Tasia Irma Endriani

DOI: https://doi.org/10.52403/ijrr.20261124

ABSTRACT

Background: Hemorrhagic stroke (HS) presenting as a lobar intracerebral hemorrhage in young adults requires a thorough etiological evaluation, especially when blood pressure at presentation is normal and there is no history of chronic hypertension. Neurological manifestations can vary depending on the location and distribution of the hemorrhage, necessitating a correlation between clinical findings and neuroimaging.

Case Presentation: A 37-year-old man experienced a sudden-onset headache, followed by a seizure lasting approximately five minutes, a transient loss of consciousness, and projectile vomiting without preceding nausea. Upon arrival at the hospital, his blood pressure was 105/56 mmHg, and his GCS score was 15. Visual acuity and visual field examinations for both eyes were within normal limits, and there was no motor weakness. A non-contrast head CT scan revealed a left occipital lobar intracerebral hemorrhage (approximately 19 mL) with perifocal edema and compression of the left lateral ventricle, but no midline shift. The working diagnosis was a lobar intracerebral hemorrhage, with a suspected arteriovenous malformation. Treatment included phenytoin, mannitol, tranexamic acid, and supportive care. Throughout his hospital stay, the patient remained conscious with preserved motor strength; his headache intensified temporarily before eventually resolving. He was discharged with a plan for follow-up MRI and MRA to investigate the underlying etiology.

Conclusion: Occipital intracerebral hemorrhage in young adults may present with seizures, even while visual and motor functions remain intact. Further vascular evaluation is essential to determine the etiology and to guide management and the prevention of recurrent hemorrhage.

Keywords: Brain Edema, Cerebral Hemorrhage, Computed Tomography Scan, Seizures

INTRODUCTION

Hemorrhagic stroke (HS)-which encompasses intracerebral hemorrhage (ICH) and subarachnoid hemorrhage-is a neurological emergency. Early mortality for ICH is reported to be as high as 30-40%.(1) In Indonesia, data from 2023 indicate a national prevalence of 8.3 per 1,000 individuals aged ≥15 years for all types of stroke.(2) Meanwhile, in Bali, a study of 96 patients with HS between 2019 and 2021

revealed that 50% of these cases involved intracerebral hemorrhage.(3) The etiology of ICH can include hypertension-related arteriolosclerosis, cerebral amyloid angiopathy, arteriovenous malformations, and cerebral venous thrombosis.(1) An analysis of the National Inpatient Sample in the United States from 2016–2022 showed that the combined diagnosis of arteriovenous malformation and aneurysm was more prevalent in patients aged 18–39 years compared to those aged ≥40 years (14.0% vs. 3.6%).(4)

Rupture of an intracerebral blood vessel can lead to the formation of perihematomal edema.(5) Clinical manifestations of intracerebral hemorrhage (ICH) include acute headache, vomiting (without preceding nausea), altered consciousness, seizures, and focal neurological deficits-such as hemiparesis, language impairment, or visual field disturbances-depending on the location of the lesion.(1,6) A non-contrast head CT scan serves as the initial modality to confirm the hemorrhage, including its location and volume.(7) Additionally, an MRI may be performed to identify cavernous malformations or neoplastic lesions, while an MRA can be used to evaluate intracranial vascular abnormalities.(1,8)

Intracerebral hemorrhage in a young adult with normal blood pressure necessitates a careful investigation into the underlying etiology. Furthermore, a neurological examination is essential to confirm the deficits resulting from the hemorrhage. This case report outlines the clinical course and diagnostic findings of an intracerebral hemorrhage in the occipital lobe of a young adult with normal blood pressure, in the absence of any visual field disturbances.

CASE PRESENTATION

A 37-year-old man was referred from Puri Bunda Hospital to the Emergency Department of Wangaya Regional General Hospital (RSUD Wangaya) following the sudden onset of a headache after taking a shower, which was followed by a fall and a single seizure lasting approximately five minutes. The seizure was characterized by jerking movements of both arms accompanied by bodily rigidity. After the seizure, the patient opened his eyes but remained unresponsive. During transport, the patient experienced one episode of projectile vomiting, which occurred without preceding nausea. Upon arrival, the patient was fully conscious, able to communicate, and complained of pain in the back of his head. There is no known medical history, such as chronic hypertension. It was reported that there was no fall involving a head injury. The patient has no prior history of medical treatment. He has a history of smoking but quit in 2018. Vital signs were as follows: blood pressure 105/56 mmHg, pulse 85 beats per minute, respiratory rate 22 breaths per minute, temperature 36.9°C, and oxygen saturation 98% on room air. Physical examination revealed isocoric pupils, 3 mm in diameter, with positive light reflexes bilaterally. Visual acuity and visual field testing for both eyes were within normal limits. There were no signs of meningeal irritation, cranial nerve paresis, or pathological reflexes. Motor strength in all extremities was 5/5.

Laboratory tests from the referring hospital on September 21, 2026, showed leukocytosis (15.19 × 10^3/μL), while hemoglobin, hematocrit, and platelet count were within normal limits. A non-contrast computed tomography (CT) scan of the head revealed a hyperdense intracerebral lesion in the left occipital lobe with a volume of approximately 19 mL, accompanied by perifocal edema that compressed and narrowed the left lateral ventricle. The sulci and gyri appeared narrowed; there was no midline shift, and the cisterns were within normal limits. The radiological impression was a left occipital intracerebral hemorrhage with associated cerebral edema (Figure 1). The working diagnosis was hemorrhagic stroke, with a suspected arteriovenous malformation (AVM). Magnetic resonance imaging (MRI) and magnetic resonance angiography

(MRA) were scheduled via the outpatient clinic to evaluate the etiology.

The patient received intravenous fluids, mannitol (with a gradual dose reduction until discontinuation), and phenytoin (100 mg three times daily, initially administered intravenously and later switched to the oral route). Intravenous diazepam was prescribed for use in the event of a seizure. Other therapies included tranexamic acid (1 g four times daily for five days), citicoline, and paracetamol. During the monitoring period from September 22–30, 2026, the patient's level of consciousness remained at a Glasgow Coma Scale (GCS) score of E4V5M6, with no decline in motor strength. Headache intensity was 3/10 on September 26–27, increased to 8/10 on September 28, then decreased to 5/10 on September 29, and reached 1/10 during the initial assessment on September 30. By the subsequent evaluation on September 30, the headache had resolved (0/10), and there were no reports of weakness. The patient was discharged following clinical improvement, with a follow-up appointment scheduled for the following week for a check-up and further imaging.

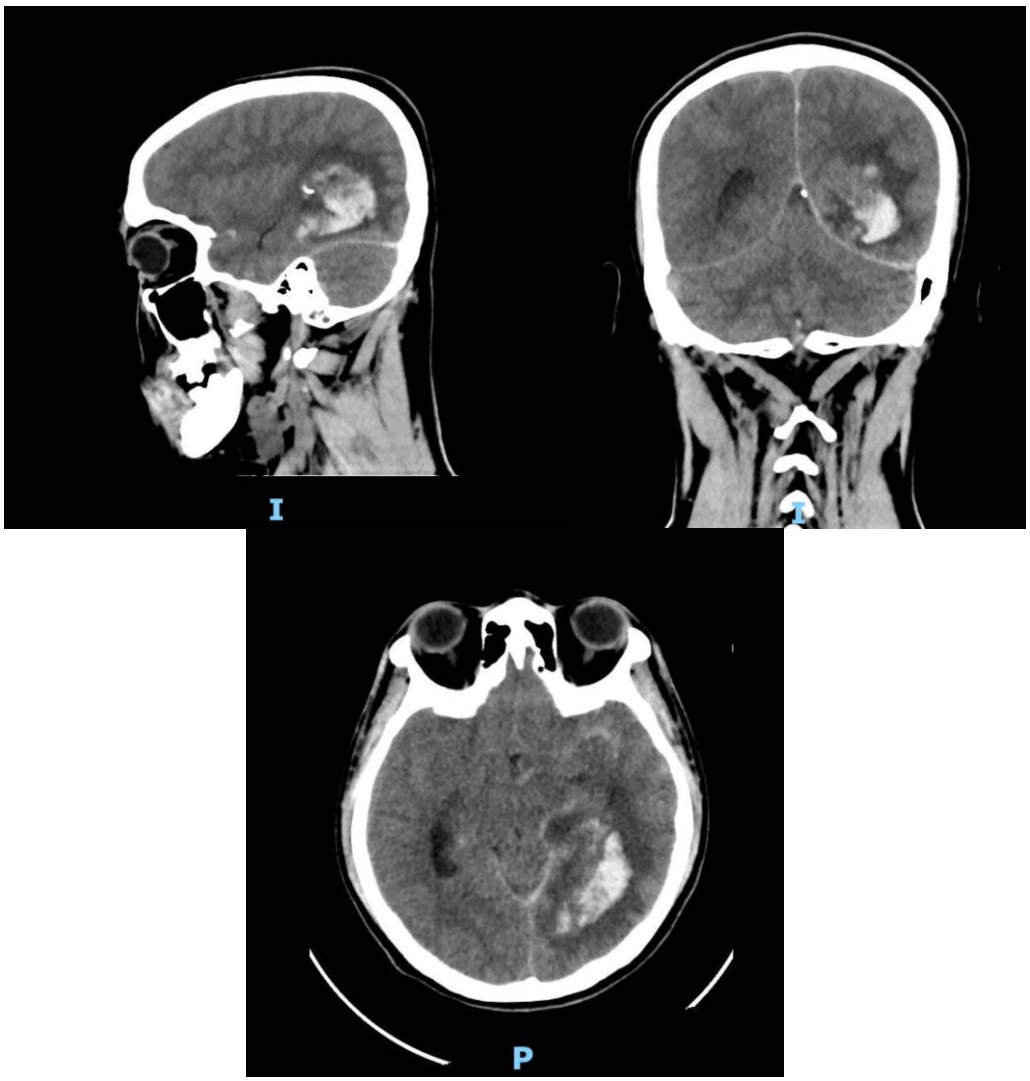

Figure 1. Non-contrast computed tomography (CT) scans of the head in sagittal (top left), coronal (top right), and axial (bottom) views, showing an intracerebral hemorrhage in the left occipital lobe, accompanied by perifocal edema and a local mass effect, with no midline shift.

DISCUSSION

This case presents three clinical findings relevant to the evaluation of a lobar intracerebral hemorrhage (ICH). First, the 37-year-old patient presented with normal blood pressure and reported no history of

chronic hypertension. Second, visual acuity and visual fields remained within normal limits, despite the hematoma being located in the left occipital lobe. Third, the patient experienced a seizure accompanied by a transient loss of consciousness. These three aspects form the basis for discussing the potential etiology of the hemorrhage, the relationship between the lesion's location and neurological function, and the mechanisms underlying the acute-phase seizure in this patient.

Regarding the first point, the patient's normal blood pressure upon hospital admission and the absence of a history of chronic hypertension must be considered in conjunction with the patient's age and the location of the hematoma. ICH resulting from hypertensive arteriolosclerosis typically involves the basal ganglia, thalamus, pons, or cerebellum; conversely, a lobar hemorrhage in a young adult is more likely to be associated with a vascular malformation or another secondary cause. (1) In this case, the combination of these characteristics strongly supports the need for vascular imaging to investigate a suspected arteriovenous malformation as a working diagnosis.

Second, the finding that visual acuity and visual fields were within normal limits is significant, given the location of the hematoma in the left occipital lobe. For comparison, Lin et al. reported on a 45-year-old woman who developed left homonymous hemianopia following an intracerebral hemorrhage (ICH) in the right occipitoparietal region. After 19 months of conservative management, serial perimetry showed a gradual improvement. (9) In contrast, the patient in this case presented with normal visual acuity and visual fields during the initial clinical examination. An anatomical hypothesis is that the distribution of the hematoma in this patient did not cause significant disruption to the primary visual cortex or the optic radiations. This hypothesis is supported by lesion-mapping research by Willis et al., which suggests that the variability in hemianopia manifestations resulting from occipital damage may be influenced by the extent of damage to the optic radiations and extrastriate visual areas. (10)

Third, the occurrence of seizures at the onset of an ICH may be linked to alterations in neuronal excitability caused by hemorrhage involving cortical tissue. Potential mechanisms include ionic imbalance, glutamate release, an inflammatory response, and blood-brain barrier dysfunction, which facilitates the entry of albumin and other mediators into the cerebral tissue. (11) In a meta-analysis of 22 studies involving 32,162 patients, Guo et al. reported a seizure incidence of 9.5%. Furthermore, a lobar location (RR 2.99) and cortical involvement (RR 3.22) were each associated with an increased risk of seizures. (6)

Other clinical manifestations include sudden-onset headache and projectile vomiting, occurring without preceding nausea. Ko et al. explain that a hematoma can increase intracranial pressure, leading to headache, vomiting, and transient impairment of consciousness. (12) Motor examination revealed an extremity strength of 5/5 throughout the course of care. Neuroanatomically, voluntary motor function relies on the frontal motor cortex and the corticospinal tracts, which pass through the corona radiata and the internal capsule. A study by Murray et al. involving 98 patients with intracerebral hemorrhage (ICH) found that involvement of the corticospinal tracts by a hematoma-particularly in the posterior portion of the internal capsule-is associated with more severe motor impairment. (13) In this case, the hematoma was located in the left occipital lobe, which is anatomically outside the primary motor areas; this is consistent with the finding that extremity strength remained normal.

A non-contrast head CT scan revealed a hyperdense lesion in the left occipital lobe (approximately 19 mL), perifocal edema, and a local mass effect-manifesting as narrowing of the left lateral ventricle and

cerebral sulci-without midline shift. Tissue changes surrounding the hematoma may involve vasogenic edema, resulting from a disruption of the blood-brain barrier that leads to the accumulation of extracellular fluid, as well as cytotoxic edema, caused by a disturbance in ion homeostasis that triggers cellular swelling. (14) Both processes can occur concurrently during the evolution of tissue injury. Further etiological investigation should consider potential underlying causes such as arteriovenous malformations, cavernous malformations, aneurysms, cerebral venous thrombosis, or small-vessel diseases. In accordance with AHA/ASA guidelines, a CT angiogram (CTA)-with consideration for venography-is recommended for cases of spontaneous lobar ICH in patients under 70 years of age. Furthermore, MRI/MRA and catheter-based angiography may be considered based on the results of initial evaluations. (1)

During treatment, the patient received therapy consisting of phenytoin following the seizure, mannitol (with a gradual dose reduction), tranexamic acid, and supportive care. The use of an anti-seizure medication after a clinical seizure is consistent with AHA/ASA guidelines. (1) A decrease in consciousness occurred following the seizure prior to hospital arrival; however, during in-hospital monitoring, the patient remained fully conscious, experiencing fluctuating headaches, with a motor strength of 5/5. Key limitations of this report include the absence of MRI/MRA results to confirm the etiology, as well as the lack of serial imaging to assess changes in the hematoma and edema. Establishing the etiology through further investigation will be essential for determining strategies to prevent recurrent hemorrhage and for guiding appropriate follow-up care.

CONCLUSION

This case illustrates the discrepancy between the location of an intracerebral hemorrhage in the occipital lobe and its neurological manifestations. Seizures presented as the initial manifestation, while visual and motor functions remained intact. These findings underscore the importance of integrating clinical evaluation with brain imaging, supplemented by further vascular assessment to confirm the etiology and plan appropriate follow-up for the patient.

Declaration by Authors

Acknowledgement: None

Source of Funding: None

Conflict of Interest: No conflicts of interest declared.

Creative Commons Attribution License 4.0

This is an open-access article published under the terms of the Creative Commons Attribution 4.0 International License (CC BY 4.0).

https://creativecommons.org/licenses/by/4.0

REFERENCES

1. Greenberg SM, Ziai WC, Cordonnier C, Dowlatshahi D, Francis B, Goldstein JN, et al. 2022 guideline for the management of patients with spontaneous intracerebral hemorrhage: a guideline from the American Heart Association/American Stroke Association. Stroke. 2022;53(7): e282–e361. DOI: 10.1161/STR.0000000000000407.
2. Badan Kebijakan Pembangunan Kesehatan, Kementerian Kesehatan Republik Indonesia. Survei Kesehatan Indonesia (SKI) 2023 dalam angka. Jakarta: Badan Kebijakan Pembangunan Kesehatan, Kementerian Kesehatan Republik Indonesia; 2024. Available from: https://www.badankebijakan.kemkes.go.id/repositori/id/eprint/5539/
3. Natha MHJ, Maliawan S, Niryana IW, Kusuma GFP. Gambaran karakteristik pasien stroke hemoragik di RSUP Prof. Dr. I.G.N.G Ngoerah Bali, Indonesia, tahun 2019–2021. Intisari Sains Medis. 2023;14(2):664–668. DOI: 10.15562/ism.v14i2.1740.
4. Urfy M, Tariq Mir M. When stroke strikes early: unusual causes of intracerebral hemorrhage in young adults. J Clin Med. 2025;14(23):8475. DOI: 10.3390/jcm14238475.
5. Samarasekera N, Tuck S, Wang X, Anderson CS, Shirazian A, Volbers B, et al. Perihematomal edema and functional

outcome after intracerebral hemorrhage: a meta-analysis of individual participant data. Stroke. 2026;57(5):1310–1324. DOI: 10.1161/STROKEAHA.125.053991.
6. Guo X, Zhong R, Han Y, Zhang H, Zhang X, Lin W. Incidence and relevant factors for seizures after spontaneous intracerebral hemorrhage: a systematic review and meta-analysis. Seizure. 2022; 101:30–38. DOI: 10.1016/j.seizure.2022.06.016.
7. Hillal A, Ullberg T, Ramgren B, Wassélius J. Computed tomography in acute intracerebral hemorrhage: neuroimaging predictors of hematoma expansion and outcome. Insights Imaging. 2022;13(1):180. DOI: 10.1186/s13244-022-01309-1.
8. Bower MM, Giles JA, Sansing LH, Carhuapoma JR, Woo D. Stroke controversies and debates: imaging in intracerebral hemorrhage. Stroke. 2024;55(11):2765–2771. DOI: 10.1161/STROKEAHA.123.043480.
9. Lin S, George BZ, Wilson-Holt NJ. Perimetric demonstration of spontaneous visual field recovery following occipital lobe haemorrhage. BMJ Case Rep. 2013;2013: bcr2013010494. DOI: 10.1136/bcr-2013-010494.
10. Willis HE, Hameed J, Starling L, Kaltenbach C, Moore MJ, Khan A, et al. Voxel-based lesion-symptom mapping localizes residual visual function in hemianopia. J Neurosci. 2025;45(9):e1263242024. DOI: 10.1523/JNEUROSCI.1263-24.2024.
11. Meijer WC, Gorter JA. Role of blood-brain barrier dysfunction in the development of poststroke epilepsy. Epilepsia. 2024;65(9):2519–2536. DOI: 10.1111/epi.18072.
12. Ko SB, Choi HA, Lee K. Clinical syndromes and management of intracerebral hemorrhage. Curr Atheroscler Rep. 2012;14(4):307–313. DOI: 10.1007/s11883-012-0251-2.
13. Murray ON, Chiuta S, Ryu P, Hanley DF, Patel HC, Harston G, et al. Corticospinal tract damage on baseline CT predicts motor recovery and functional outcome in intracerebral haemorrhage. Eur Stroke J. 2025;10(4):1383–1391. DOI: 10.1177/23969873251332769.
14. Wan Y, Holste KG, Hua Y, Keep RF, Xi G. Brain edema formation and therapy after intracerebral hemorrhage. Neurobiol Dis. 2023; 176:105948. DOI: 10.1016/j.nbd.2022.105948.

How to cite this article: Tasia Irma Endriani, Ni Wayan Bunga Pandansari, Desie Yuliani, Ni Made Kurnia Dwi Jayanthi. Occipital lobar intracerebral hemorrhage in a normotensive 37-year-old man: a case report. *International Journal of Research and Review*. 2026; 13(11): 271-276.
DOI: *https://doi.org/10.52403/ijrr.20261124*

******